Ultrasound and optoacoustic imaging
Part II: Advanced ultrasound imaging

Xosé Luís Deán-Ben, PhD

xdeanben@ethz.ch

23.04.2026

Today's topic

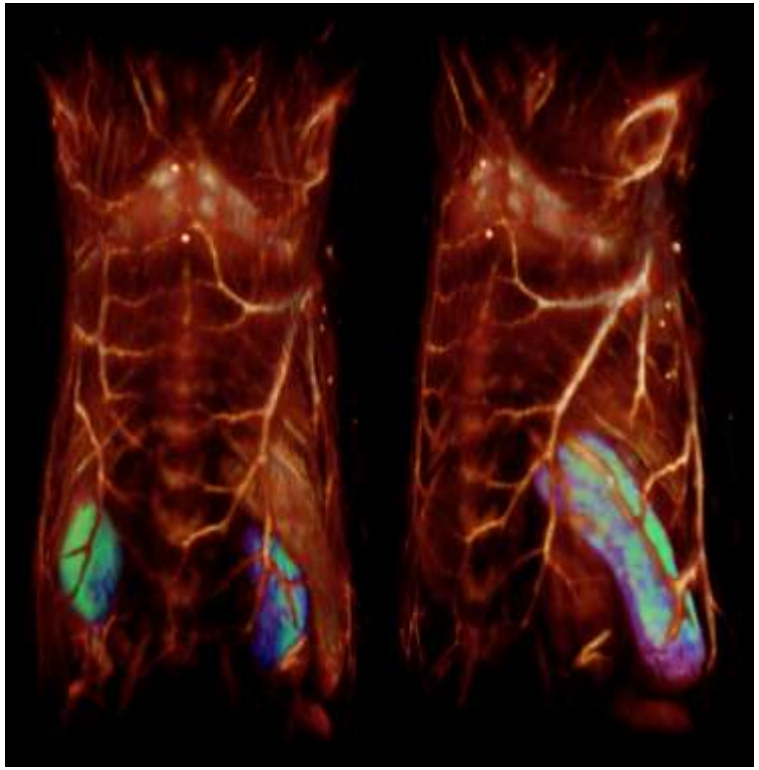

Learning objectives

Part I: Ultrasound in biology and medicine

Part II: Advanced ultrasound imaging

Part III: Optoacoustic imaging

Obstetrics

Obstetric (prenatal) ultrasound renders anatomical images of a baby (embryo or fetus) within a pregnant woman, as well as the mother's uterus and ovaries

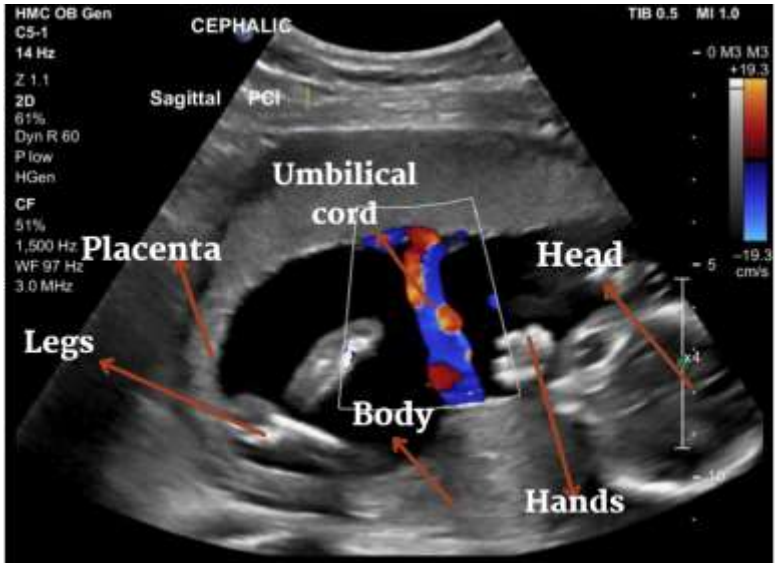

Doppler ultrasound can additionally evaluate blood flow in the umbilical cord, fetus or placenta

The gestational sac is surrounded by hyperechoic (brighter) body tissues

Early pregnancy

Gestational sac, yolk sac and embryo at 5 weeks gestational age

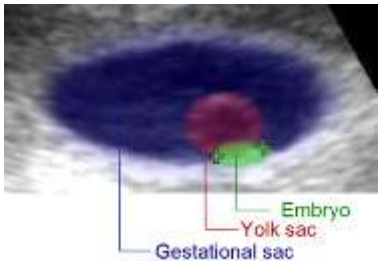

Heartbeat at 7 week gestational age

The sex of the fetus can be discerned by ultrasound at 11 weeks gestational age

Gestational Age	King's College Hospital Medical School	Taipei City Hospital & Li Shin Hospital
11 weeks	70.3%	71.9%
12 weeks	98.7%	92%
13 weeks	100%	98.3%

Four-dimensional (4D) ultrasound

A sequence of 3D ultrasound images (**4D ultrasound**) can be acquired to visualize the motion of the fetus

Anatomical imaging of the human body

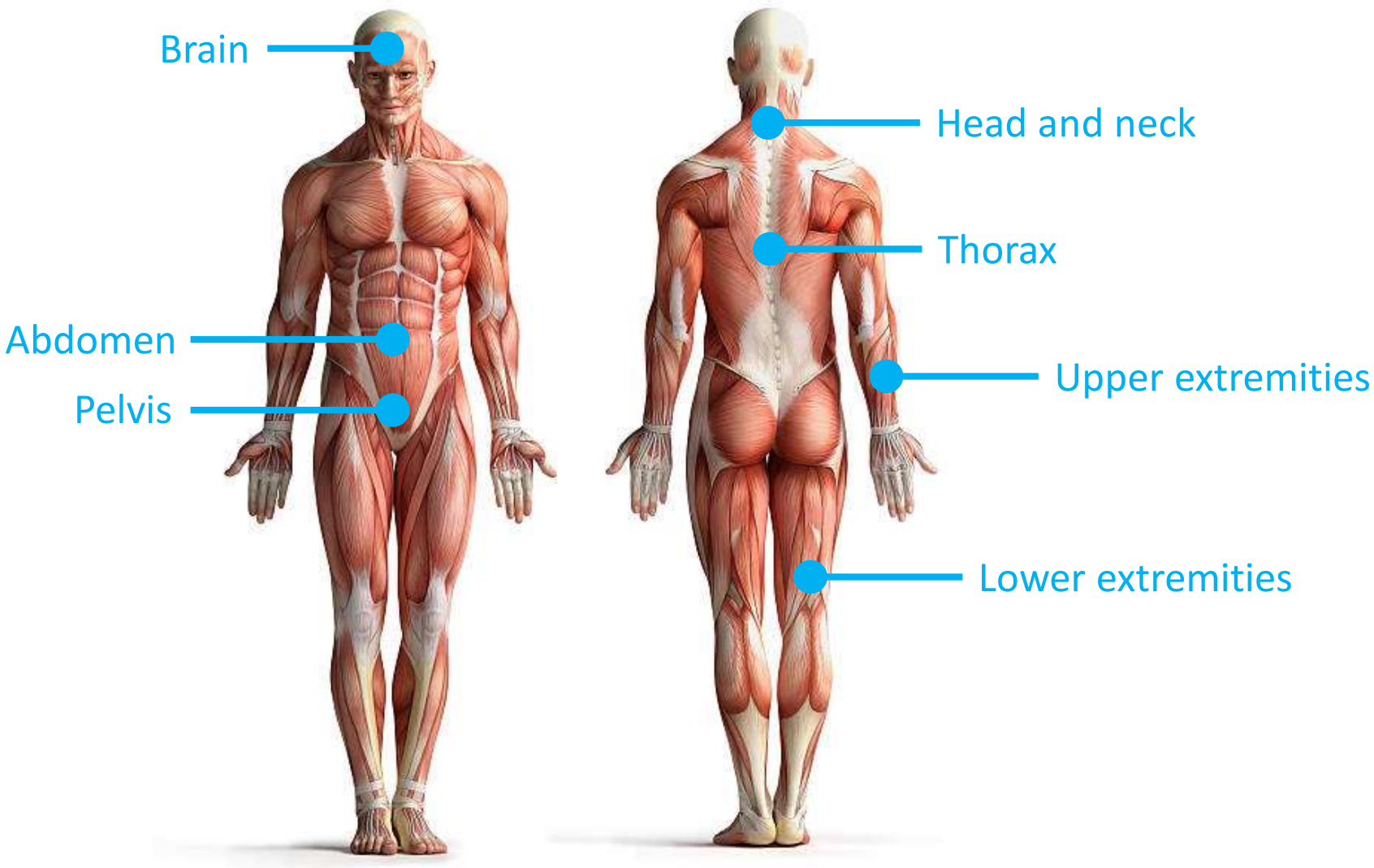

Applications

Assessing brain malformations

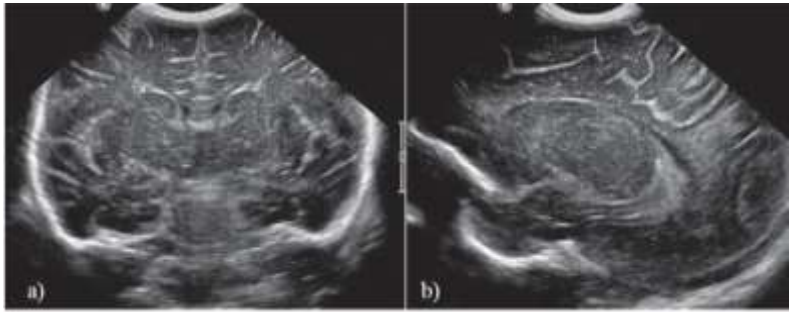

Assessment aneurysms

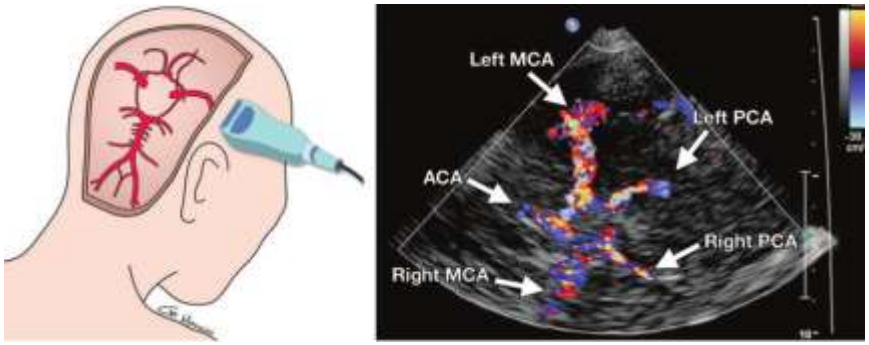

Atherosclerotic plaques

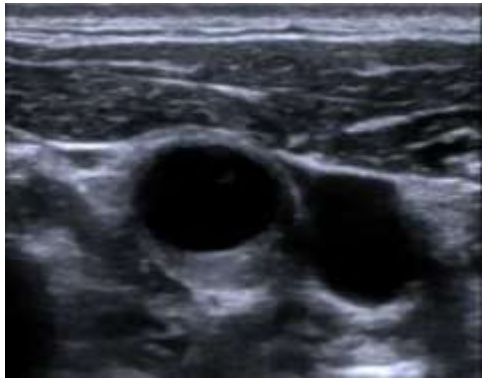

Thyroid cancer

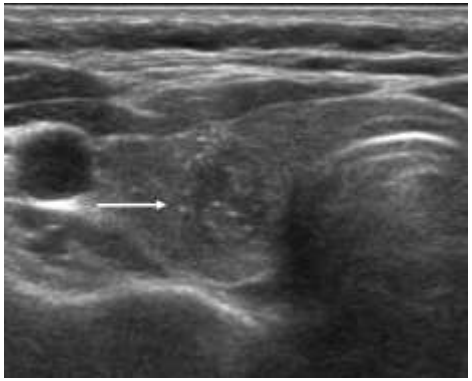

Cervical metastatic lymph nodes

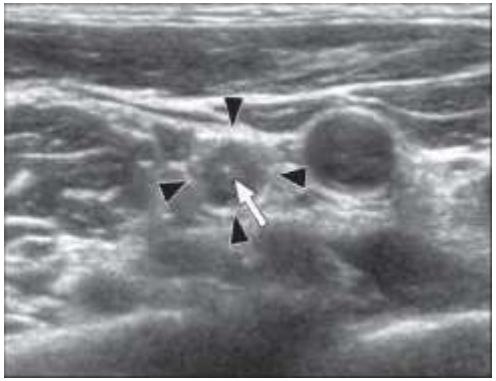

More applications

Heart diseases

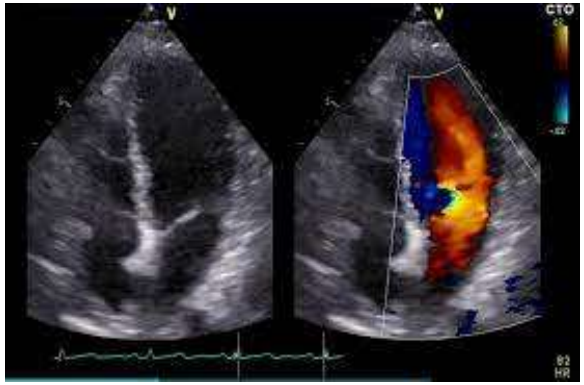

Breast cancer

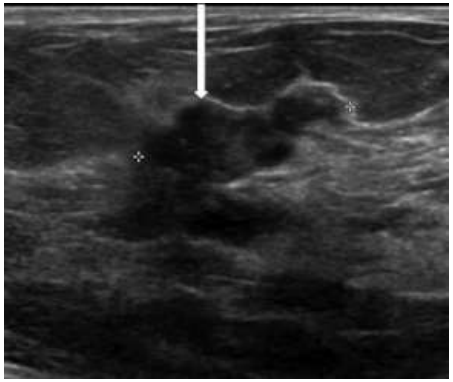

Liver cancer and metastasis

Pancreatic cancer

Kidney perfusion

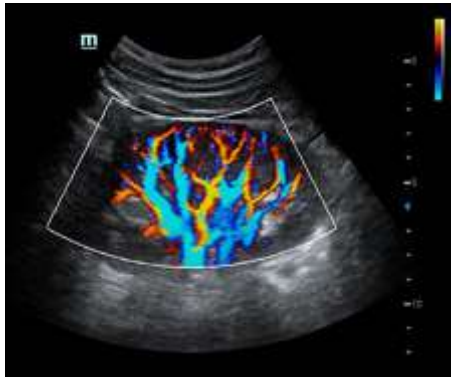

Contrast agents

A **contrast agent** (or contrast medium) is a substance used to increase the contrast of structures or fluids within the body in medical imaging

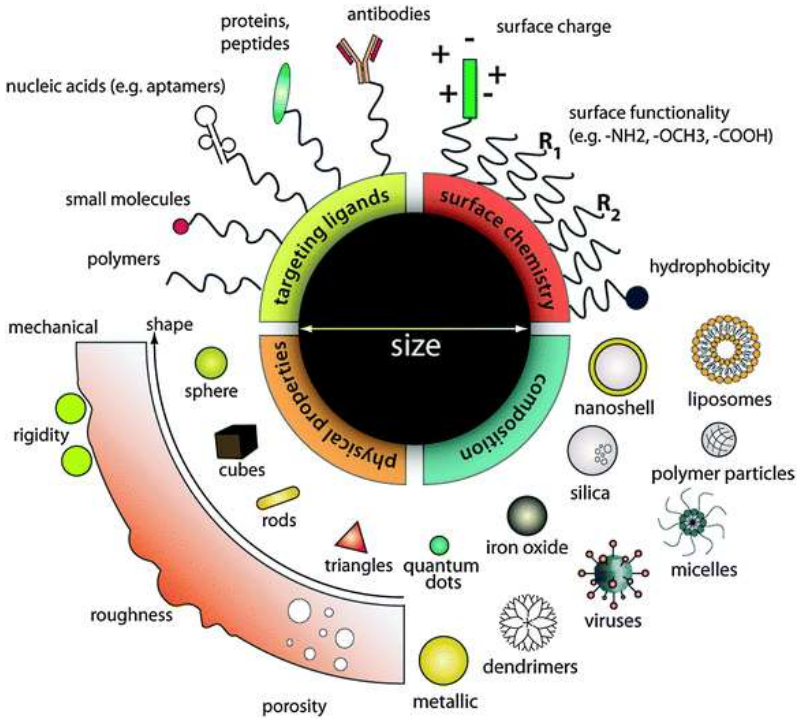

Different administration routes are possible, **blood pool agents** are intravenously injected into the bloodstream to improve the visibility of blood vessels

Contrast-enhanced ultrasound imaging

Following intravenous (i.v.) injection, microbubbles create **hyperechoic dynamic contrast** in the ultrasound images

Good old concept

The first ultrasound imaging attempts were based on immersing the human body in a water tank to acquire ultrasound data from multiple views

The use of ultrasound waves transmitted through the body was also suggested in these early days (1950s)

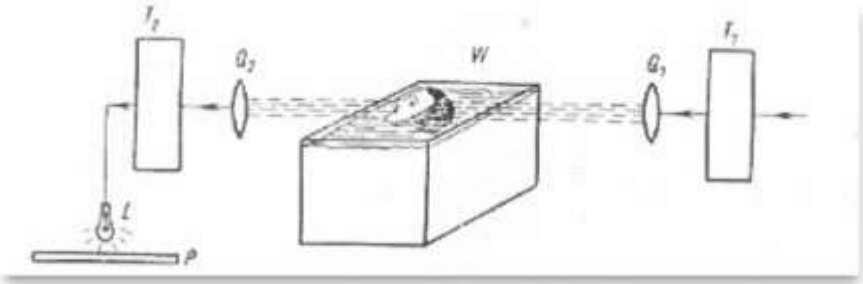

T1 -- ultrasonic generator, Q1-- transmitter, Q2 -- receiver, T2 -- converter amplifier, W -- waterbath, L -- light, P -- photographic/ heat-sensitive paper *

Breast cancer

Organised screening programmes for early detection of breast cancer in asymptomatic women have been developed

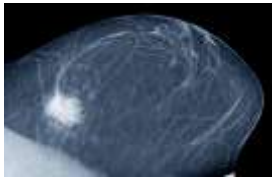

Mammography (x-rays) ✗ Ionizing radiation, discomfort

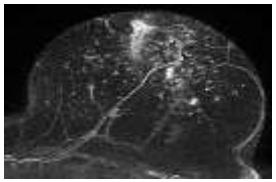

Magnetic resonance imaging (MRI) ✗ Expensive, low specificity

Ultrasound (pulse-echo) ✗ Operator dependent, low specificity

Transmission ultrasound tomography

Ultrasound transmission tomography (UTT) is a form of tomography involving ultrasound

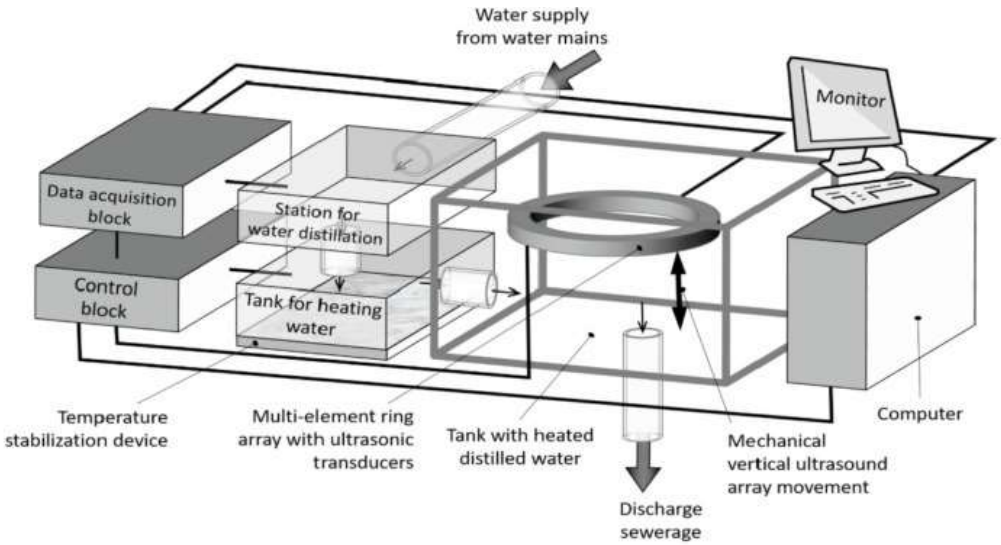

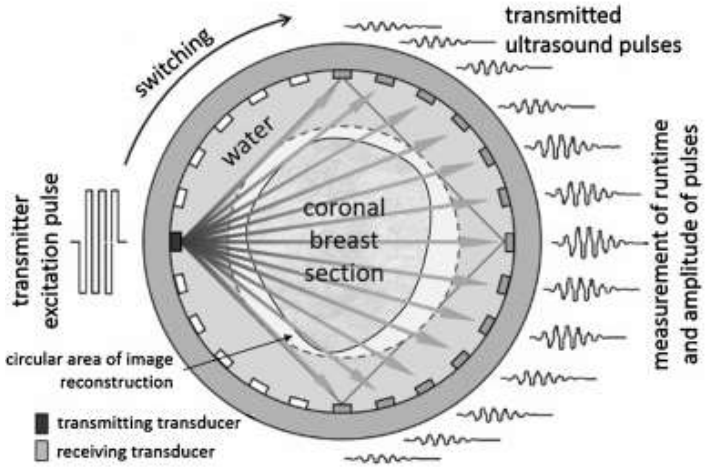

Breast cancer imaging

Entire cross-sections of the female breast can be reconstructed



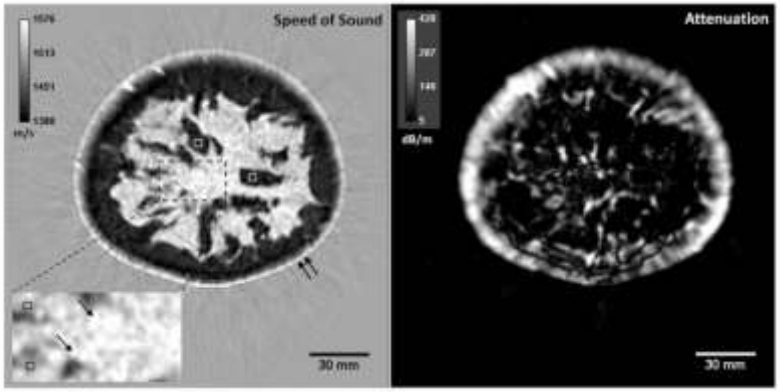

The reconstructed speed of sound images are comparable to those rendered with magnetic resonance imaging

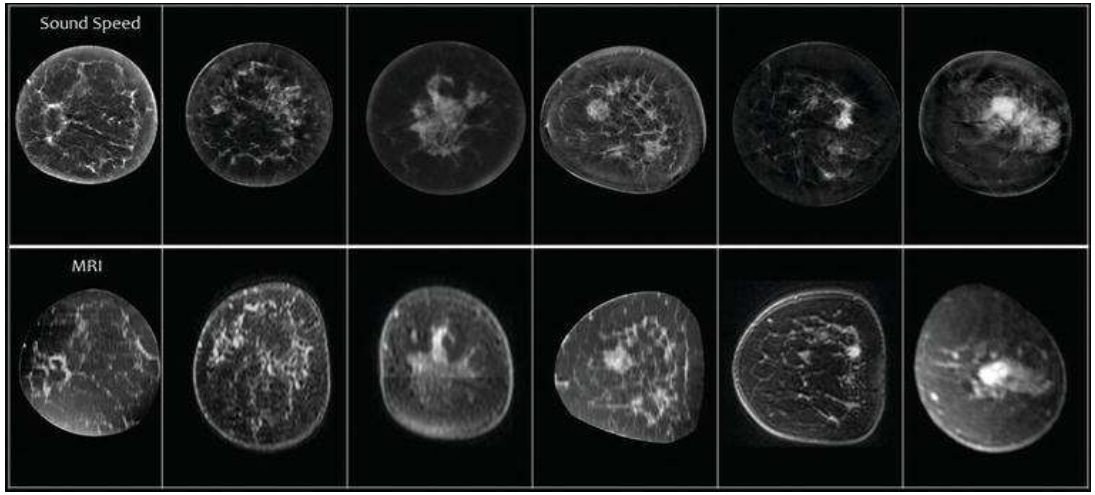

Ultrasound computed tomography

Ultrasound computed tomography (USCT) is a form of medical ultrasound tomography transmitted in direction of the measurement object and received with other or the same ultrasound transducers

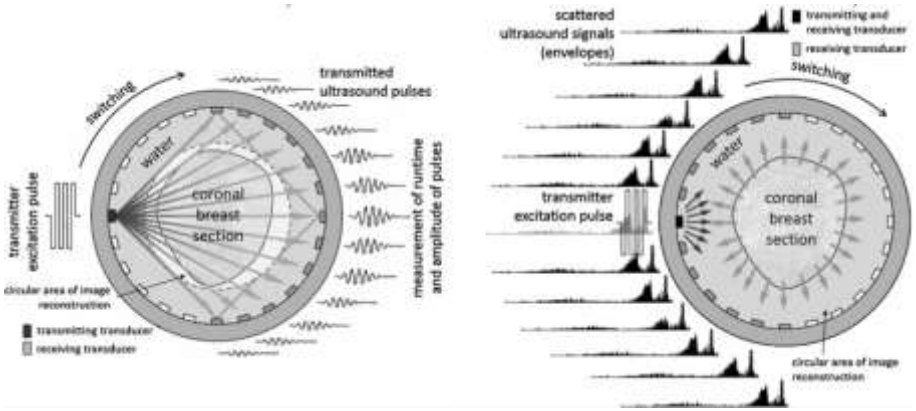



Pulse-echo (reflection) images can also be reconstructed

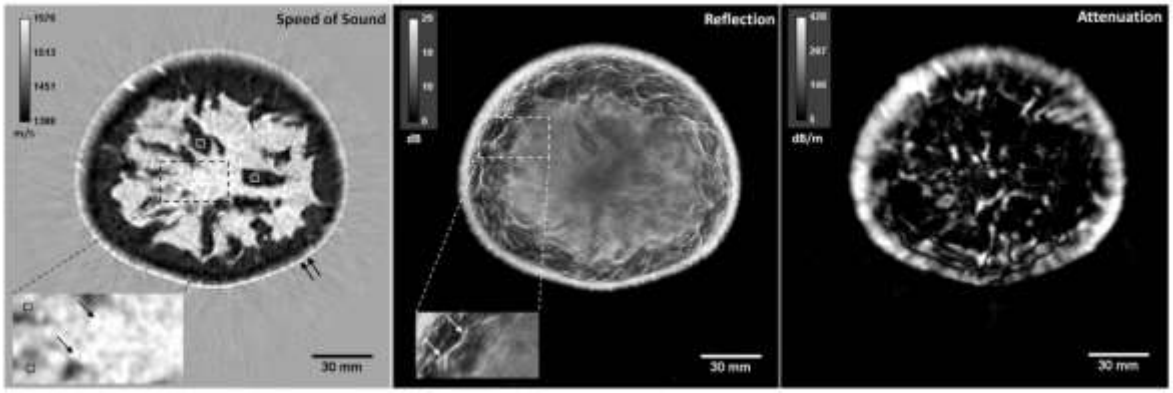

Technology evolution

Apart from scientific innovations, progress in ultrasound imaging is driven by **technology enablers**

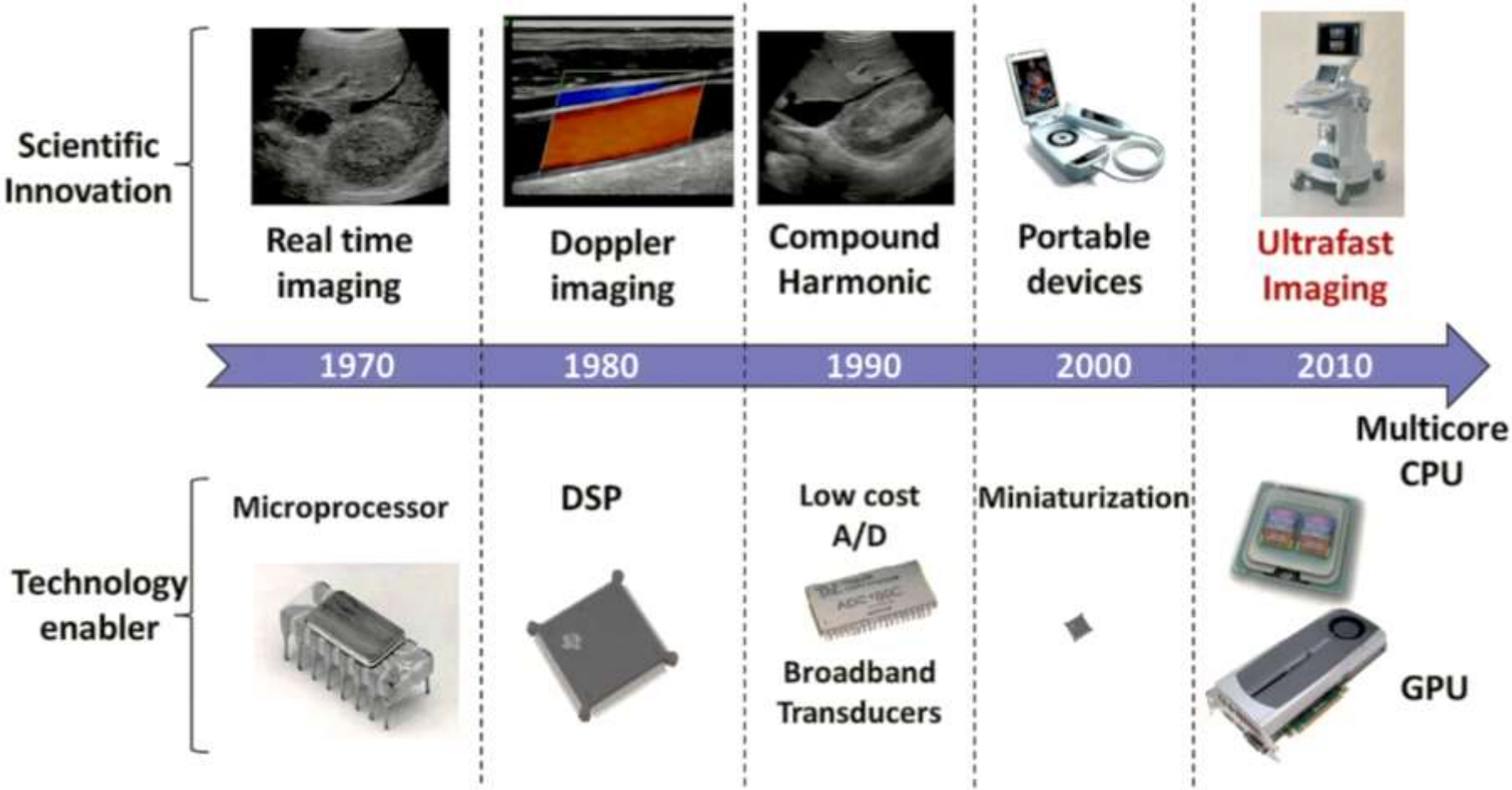

Plane wave excitation

An alternative to the standard line-by-line excitation approach used in traditional pulse-echo imaging is to use a **plane (unfocused) ultrasound wave** to simultaneously excite the entire region

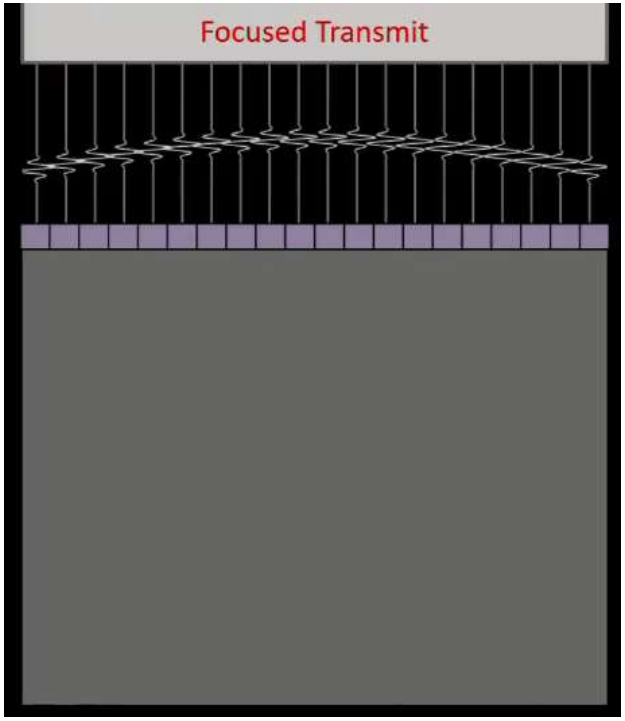

Line-by-line excitation

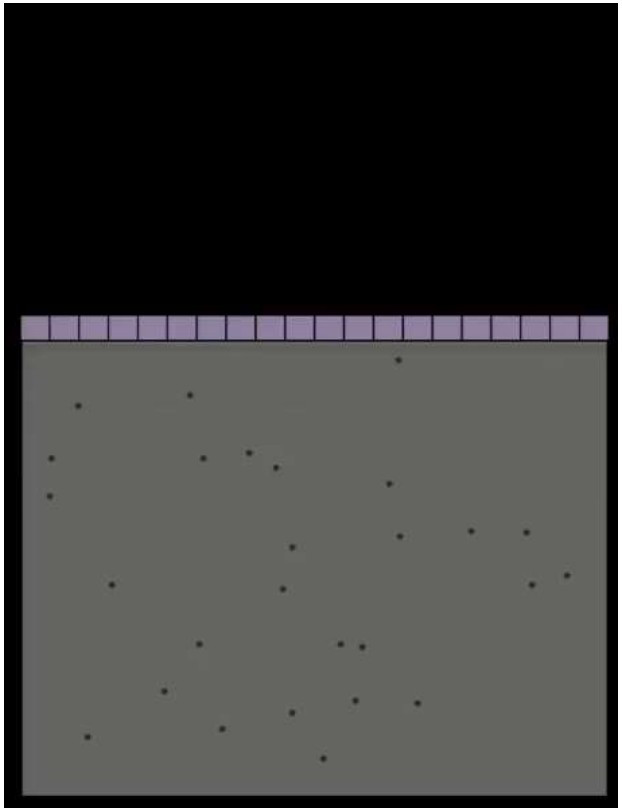

Plane wave excitation

Compounding

Ultrasound compounding is used to combine sonographic information captured from different angles and produce a single image with enhanced contrast and reduced speckle noise



Coherent compounding consists in adding up “unprocessed” images

Incoherent compounding consists in adding up “processed” images (envelope detection, logarithmic compression,…)

Ultrafast vs traditional pulse-echo imaging

Coherent compounding increases contrast-to-noise ratio and enables higher frame rates than the standard approach

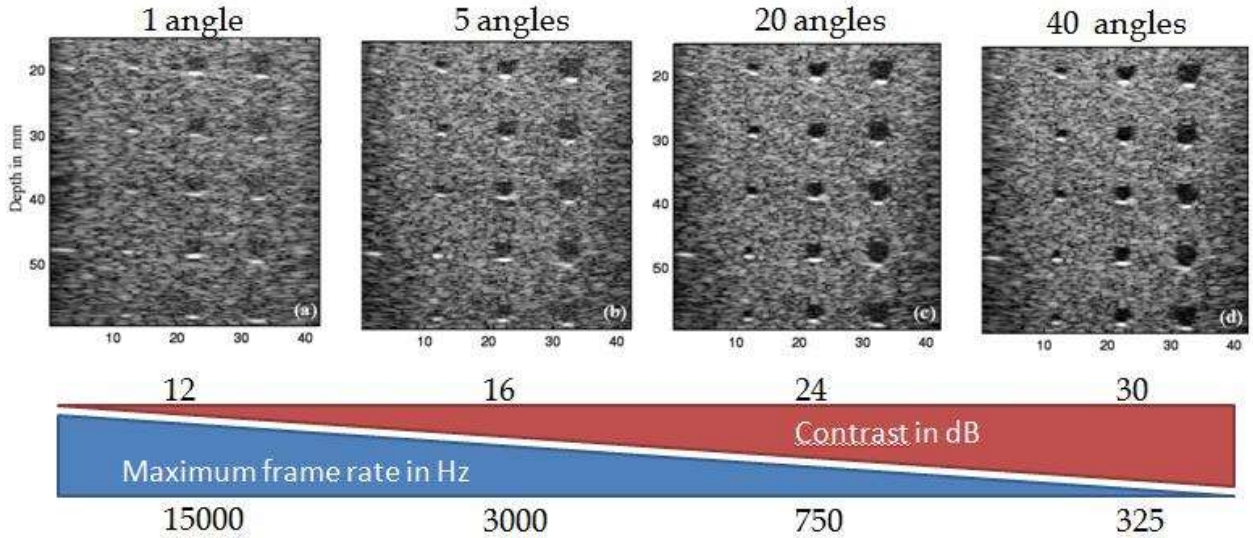

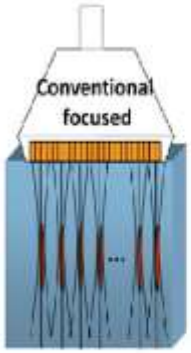





Neuroimaging

Transient neural activity is linked to subsequent changes in cerebral blood flow by means of a mechanism termed **neurovascular coupling**

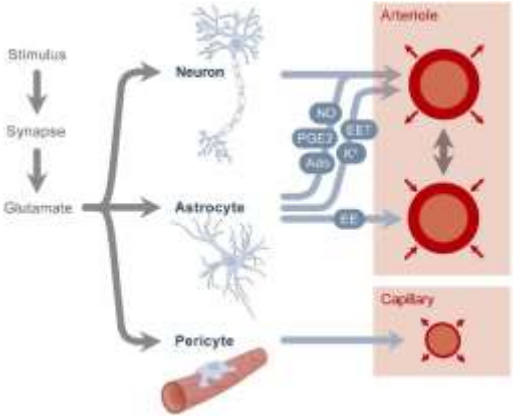

Doppler imaging with high temporal resolution enables visualizing these blood flow changes

Example: rat model of epilepsy

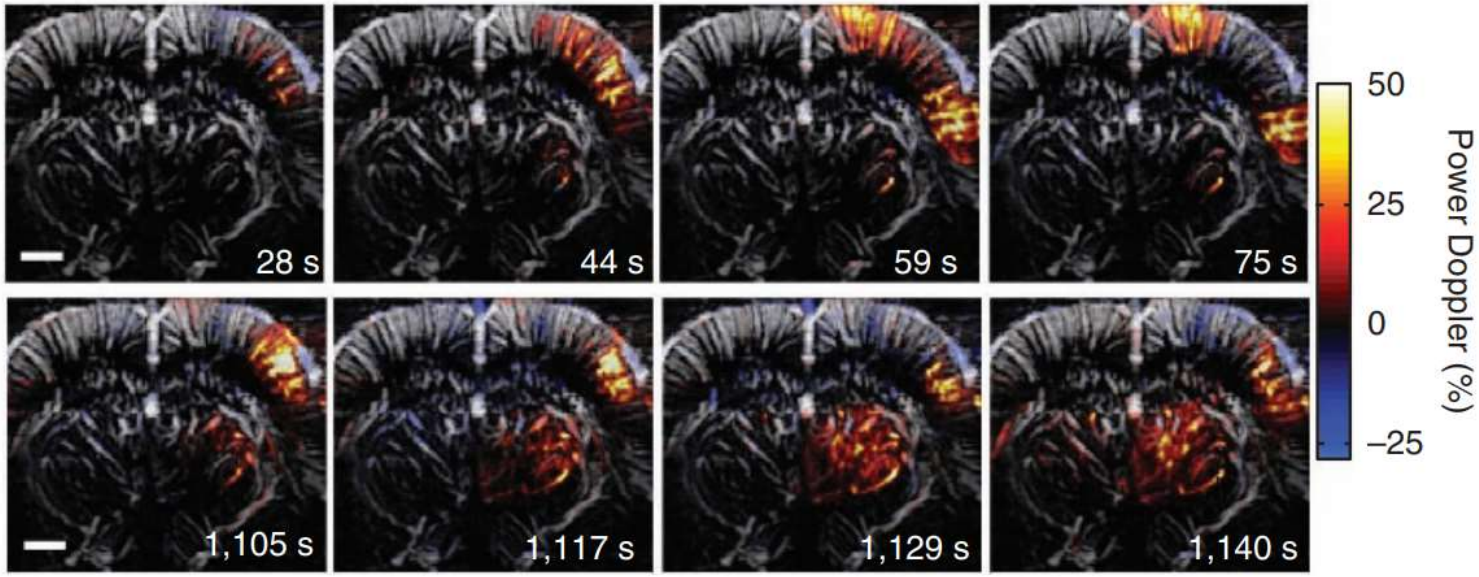

Since time immemorial

Hippocrates, the “father of medicine” started observing and experimenting with examination as the principal approach-inspection, **palpation** and auscultation are still important tools for diagnosis today

Pathological processes may change tissue stiffness e.g. due to excessive cell formation or fibrotic (scarring) processes

As part of their training, medical practitioners learn how to recognize problems on or below the surface of the skin by touch alone

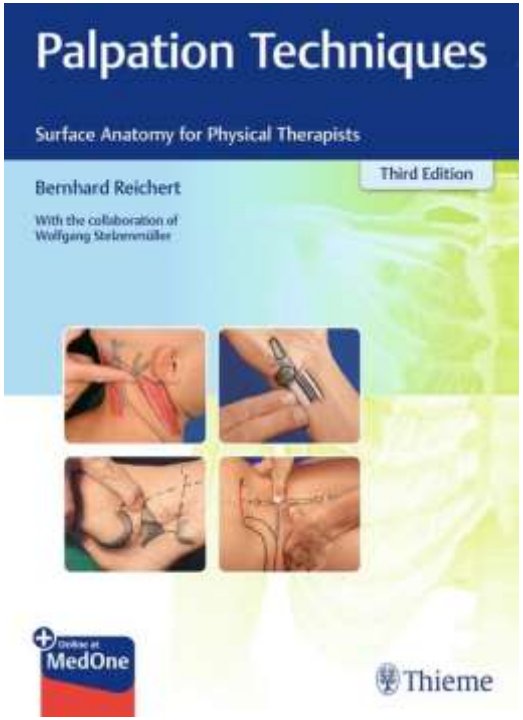

Ultrasound elastography

Ultrasound elastography techniques take advantage of changed soft tissue elasticity in various pathologies to yield qualitative and quantitative information that can be used for diagnostic purposes

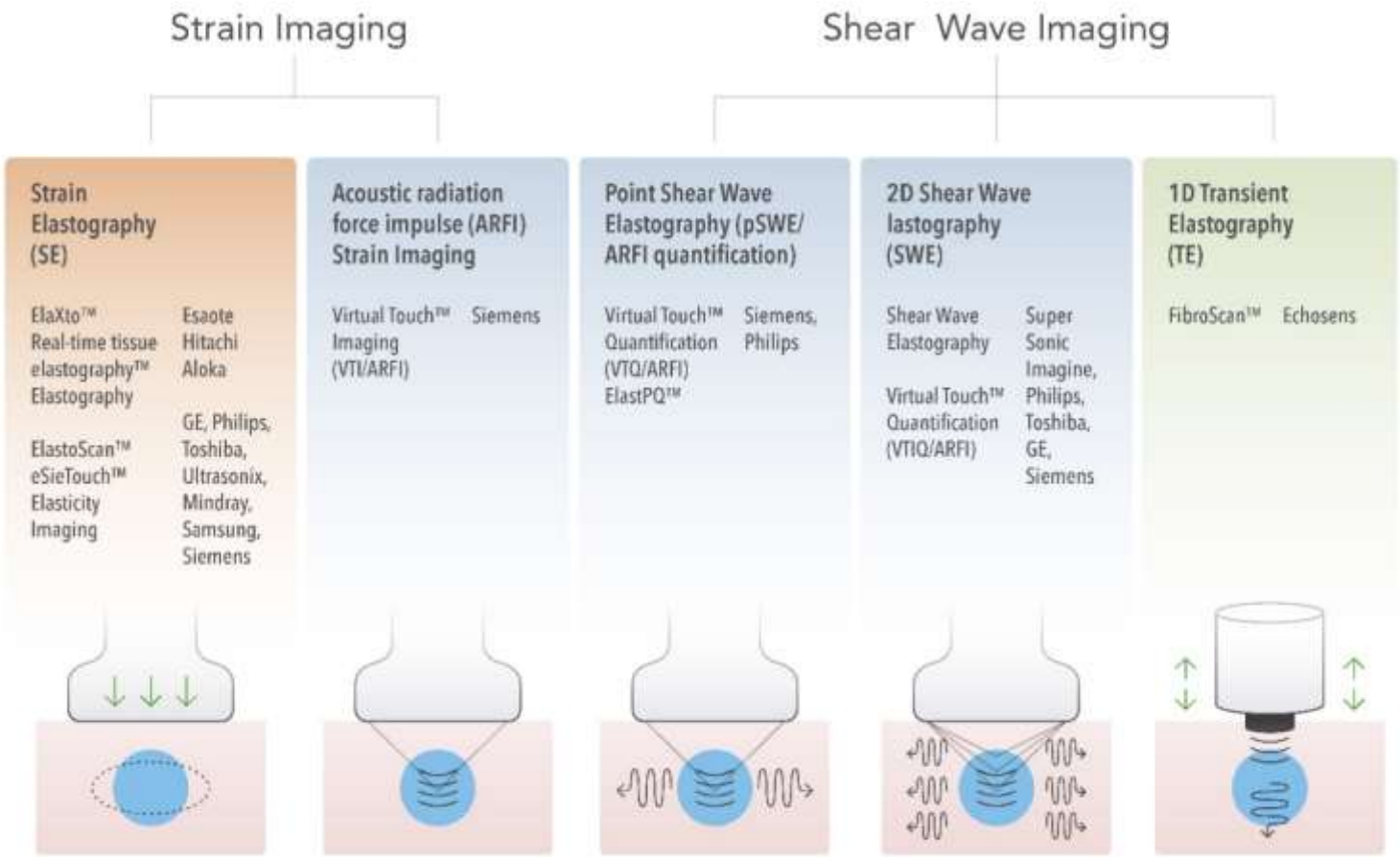

Shear wave imaging

An acoustic radiation force impulse (ARFI) also generate **shear waves** perpendicular to the acoustic radiation force

Diverging wave

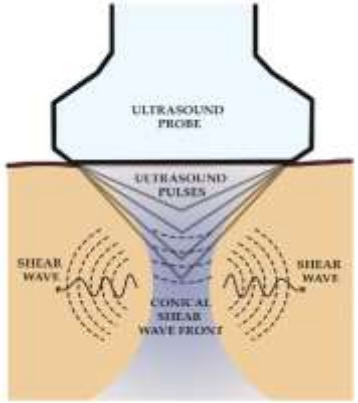

Plane wave

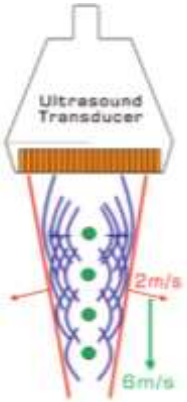

Ultrafast ultrasound can be used to visualize the propagation of the shear wave and map the shear wave velocity



Revisiting the diffraction limit

In diffraction-limited imaging systems, points separated a distance larger than the width of the point spread function cannot be resolved

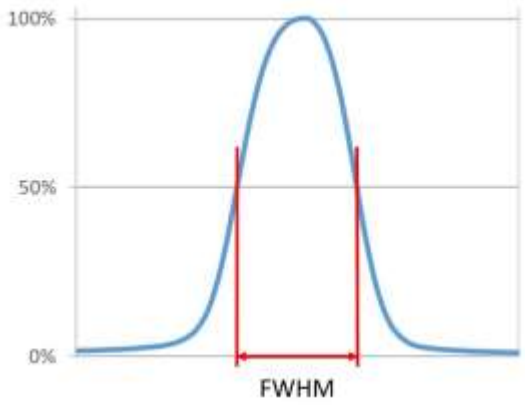

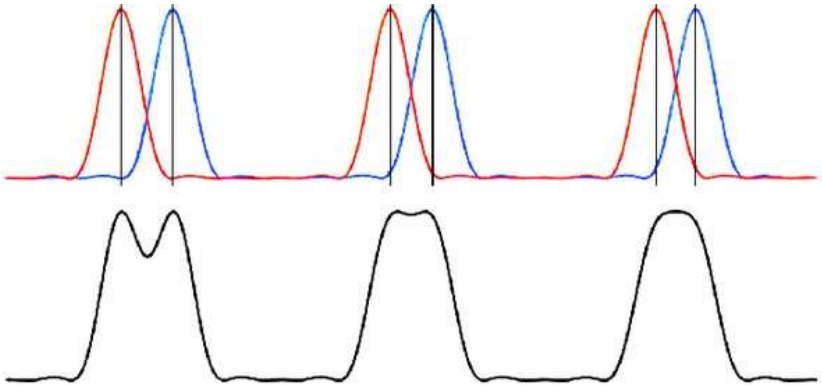

…but the position of individual sources can be estimated (localized) with a significantly higher accuracy than the diffraction limit

real sample **imaged sample**



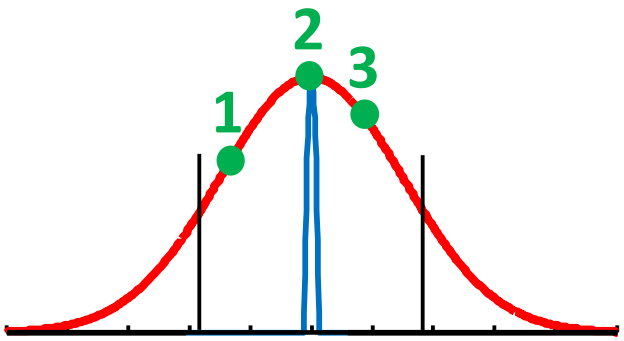

Localization imaging

If individual sources can be separated in time, **super-resolution imaging** is possible by superimposing the localized positions of all sources

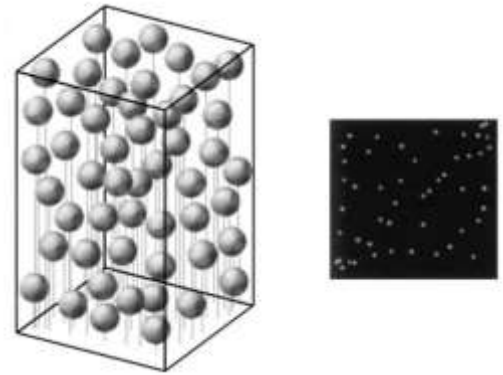

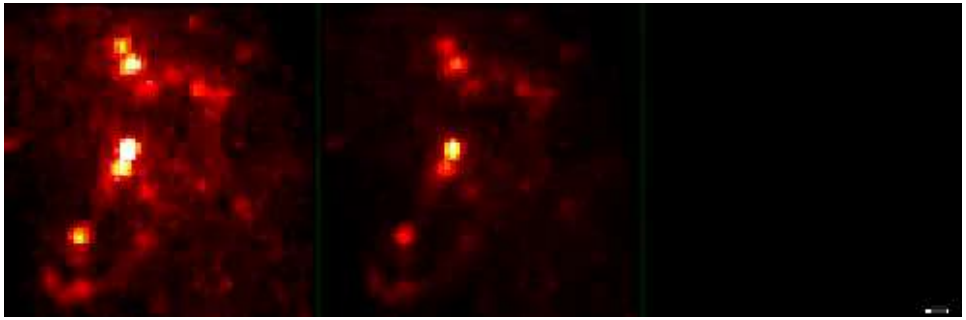

As the number of localized points is increased, the superposition of points converges to a continuous image



Localization of individual microbubbles

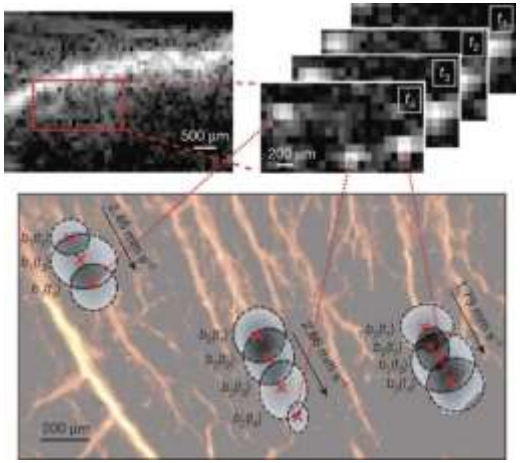

Microbubbles can be individually detected with ultrafast ultrasound!

Superimposing the localized positions of all bubbles enables rendering an image with a resolution beyond the **acoustic diffraction barrier**

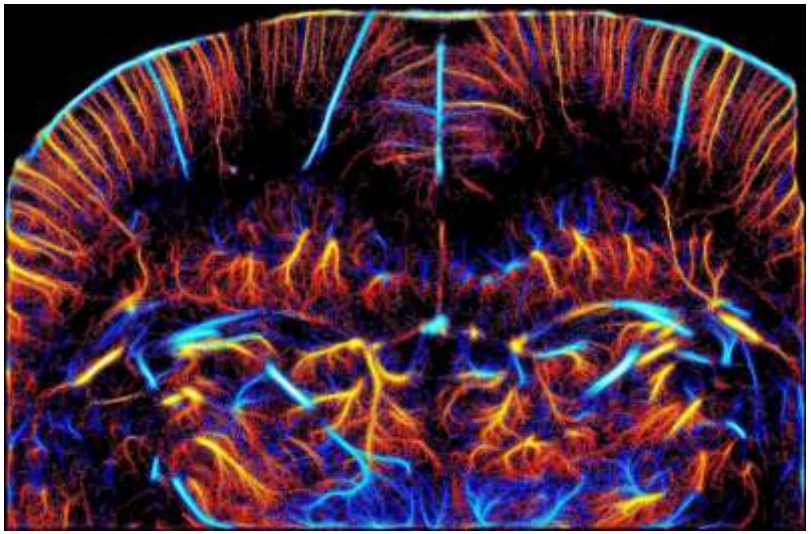

Blood flow velocity

Tracking of particles with high temporal resolution further enables quantifying blood flow velocity



…and functional neuroimaging is possible

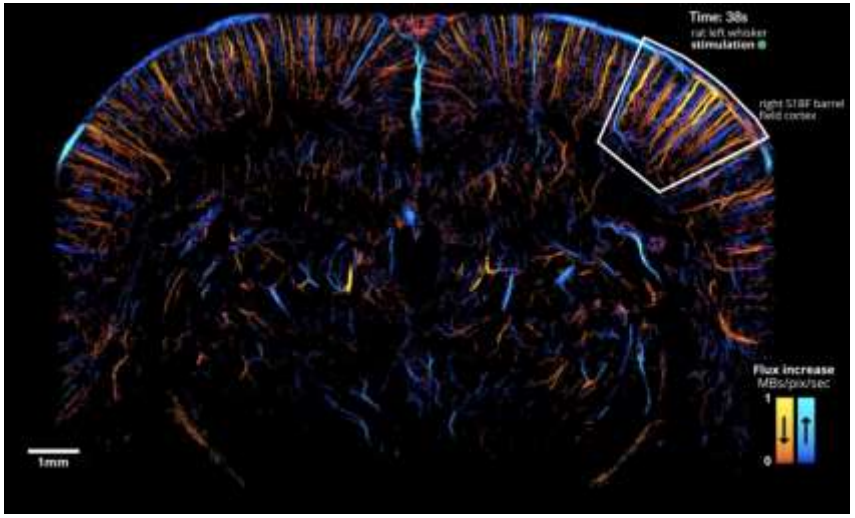

Laser ultrasound inside a tissue

Laser generation of ultrasound based on thermoelastic expansion is non-destructive (non-invasive) and occurs in any substance absorbing light

There are light absorbing molecules (chromophores) inside biological tissues

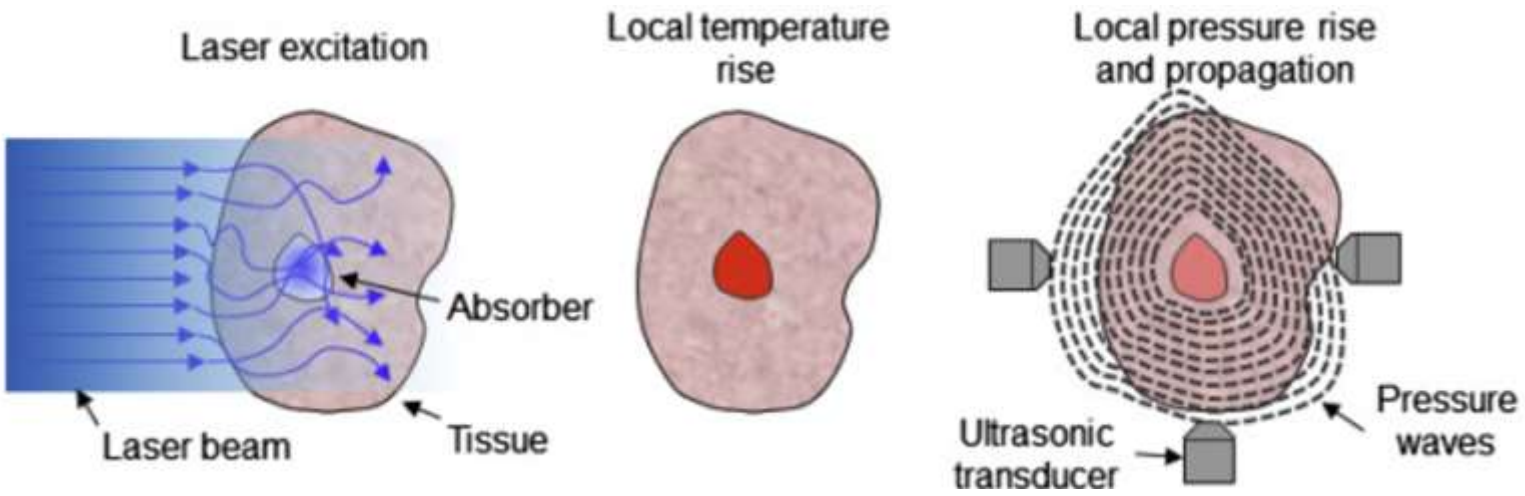

Longitudinal waves are mainly generated within a sample, which are the main type of waves that propagate in soft biological tissues

Listening to molecules

The optoacoustic contrast mechanism based on optical absorption at multiple wavelengths can be exploited to detect multiple types of endogenous and exogenous molecules and nanoparticles

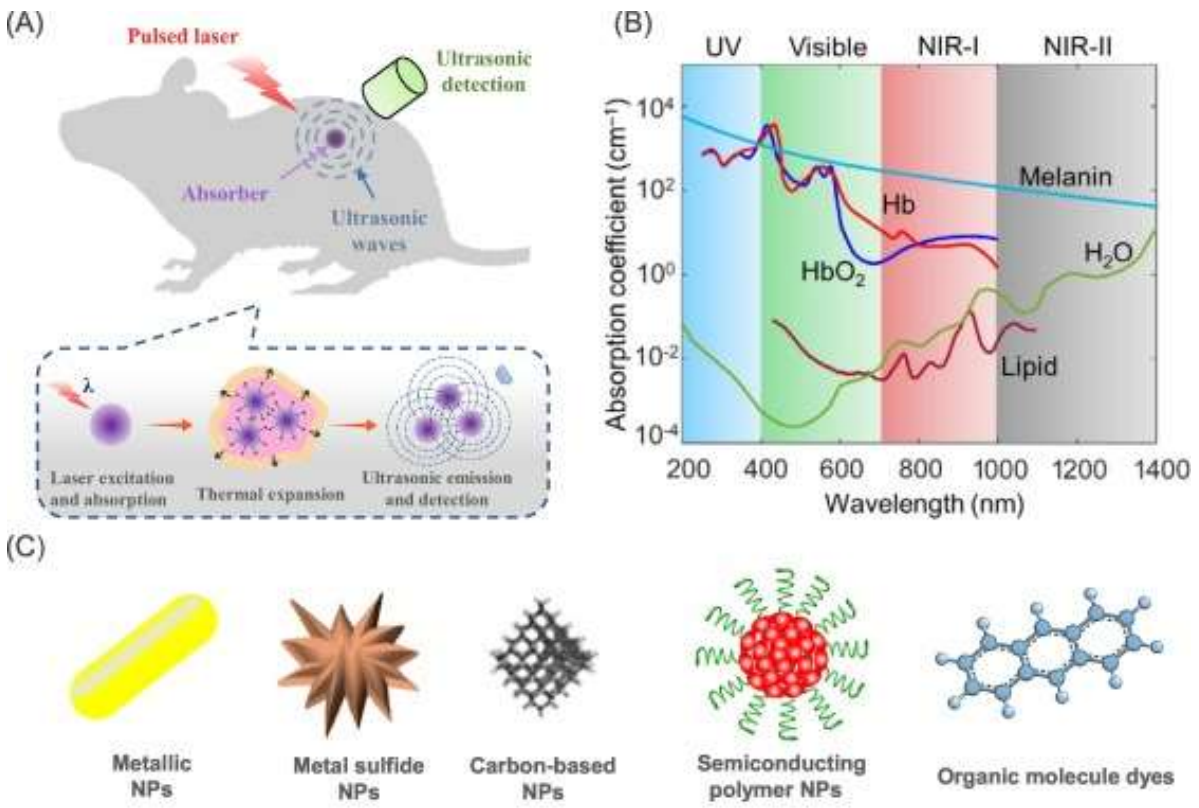

Zhang et al. Development of second near-infrared photoacoustic imaging agents. Trends in Chemistry, 3(4), 305-317 (2021)

What is next?

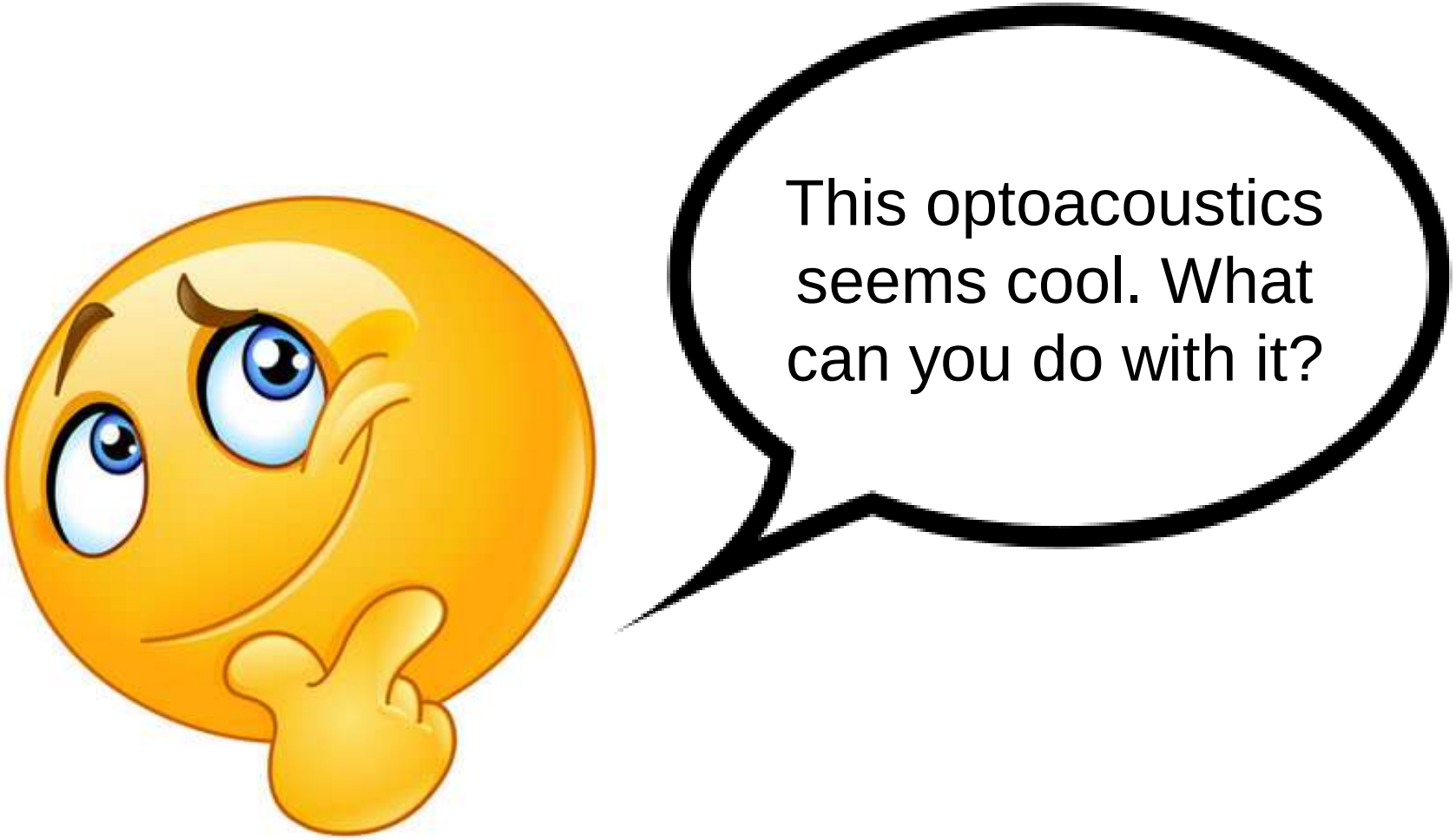

Thank you